

ВОЗМОЖНОСТИ КАРДИОХИРУРГА ПО ЗАМЕНЕ МИТРАЛЬНОГО КЛАПАНА

А. ИБН СИДИКИ*, А.Н.ЛИЩУК**, А.Г. ФАЙБУШЕВИЧ*, Д.В. ИВАНОВ***

**Российский университет дружбы народов (РУДН-Университет),
ул. Миклухо-Маклая, д. 6, Москва, 117198, Россия*

***ФГБУ «3 Центральный военный клинический госпиталь им. А.А. Вишневецкого» Министерства обороны
Российской Федерации, д. Новая - больница, Архангельское, Красногорский район, Московская область,
143421, Россия, e-mail: Alexlischuk@yandex.ru*

****Тульский государственный университет, Медицинский институт,
ул. Болдина, д. 128, Тула, 300012, Россия, e-mail: doctor_ivanov@inbox.ru*

Аннотация. С каждым годом у все большего числа людей диагностируют заболевания, связанные с повреждением митрального клапана. Это обусловлено легкой доступностью эхокардиографического оборудования и увеличением продолжительности жизни населения в целом. Мы рассмотрели литературу (*ScienceDirect, Google Scholar, PubMed*) по 4 ключевым терминам: 1) восстановление митрального клапана; 2) замена митрального клапана; 3) митральная аннулопластика; 4) перикард в кардиохирургии. Успехи в здравоохранении определяются тем, что люди больше не умирают от простых инфекционных заболеваний. Это, в свою очередь, сфокусировало внимание на более сложных патологиях, таких как болезни клапанов сердца, а также на рекомендациях хирургического вмешательства даже у бессимптомных пациентов. Замена клапана совместно с аннулопластикой стали стандартным лечением заболевания митрального клапана. Пока еще нет протезного кольца, которое укрепляет митральное кольцо без нарушения его нормальной динамики. Кольцо, сделанное из ткани перикарда, является наиболее близким к описанию Карпентье оптимального аннулопластического кольца. Широкое внедрение протезных колец затруднило исследование пригодности аутологичного перикарда для аннулопластики.

Ключевые слова: митральная регургитация, восстановление митрального клапана, замена митрального клапана, перикард.

A CARDIAC SURGEON'S PERSPECTIVE OF MITRAL VALVE REPAIR

A. IBN SIDIKI*, A.N. LISHUK**, A.G. FAIBUSHEVICH*, D.V. IVANOV***

**People's Friendship University of Russia (RUDN-University),
Mikluho-Maclaystr.,6, Moscow,117198, Russia, e-mail: dr.abusidik@yahoo.com*

***FSBI «"3 Central Military Clinical Hospital named after AA Vishnevsky" of the Ministry of Defense of the Russian Federation, vil. New – hospital, Arkhangelskoe, Krasnogorskiy district, Moscow region, 143421, Russia
e-mail: Alexlischuk@yandex.ru*

****Tula State University, Medical Institute, Boldin Str., 128, Tula, 300012, Russia
e-mail: doctor_ivanov@inbox.ru*

Abstract. From year to year, more and more people are diagnosed with *mitral disease* (MVD) and for that matter, *mitral valve failure* (MVF). This can be explained by the easy accessibility of echocardiographic equipment and increasing life expectancy of the general population. We reviewed the literature (*ScienceDirect, Google Scholar, PubMed*) under 4 key terms: (1) mitral valve repair; (2) mitral valve replacement; (3) mitral annuloplasty; (4) pericardium in cardiac surgery. Improvements in healthcare mean that, people no longer die of simple infectious diseases. This has shifted attention to more complex pathologies like *valve heart diseases* (VHD) to the extent that surgery is at times recommended even in asymptomatic patients. Valve repair plus annuloplasty has become the standard treatment for MVD. There is not yet a prosthetic ring that reinforces the mitral annulus without disruption of its normal dynamics. A ring made from pericardial tissue is the closest to Carpentier's description of an optimal annuloplasty ring. Wide adoption of prosthetic rings has hindered research into the suitability of autologous pericardium for annuloplasty.

Keywords: Mitral regurgitation, Mitral valve repair, Mitral valve replacement, Pericardium.

Introduction. *Mitral valve disease* (MVD) is a common pathology affecting people of all geographical locations, races, genders and age groups. The Framingham study reported that MVD affects 2.5% of men and 7.6% of women. It has also been diagnosed as the most common human valve disease thanks to the easy availability of diagnostic echocardiography equipment. *Degenerative MVD* (dMVD) is predominant in developed nations whereas *rheumatic MVD* (rMVD) is the most common MV pathology in developing countries. Medical

management of MVD alleviates the symptoms of heart failure and it is usually reserved for patients with grave co-morbidities deemed too risky for surgery or for patients in the asymptomatic stages of *mitral valve failure* (MVF). Ever since Elliot Cutler performed the first *mitral valve repair* (MVr) in 1923, there have been significant progress in *mitral valve* (MV) surgery. The advent of extracorporeal circulation, made MVD more operable. The available mini-invasive and transcatheter techniques have made MV surgery simpler.

The 2017 guidelines of the European Society of Cardiology/European Association for Cardio-Thoracic Surgery (ESC/EACTS) is a source of recommendations for MV surgery. Higher preoperative NYHA class and *left ventricular end diastolic diameter* (LVEDD) are negative prognostic factors for late survival in MVr and so early surgery is recommended in MVF [49]. When surgery is not delayed, survival and *quality of life* (QoL) are similar to those of the general population [52]. The 10-year survival in medical management of severe *MV insufficiency* (MVI) is reported to be as low as 27%-60% making MV surgery the optimal treatment method unless categorically contraindicated [42].

Superiority of mitral valve repair over replacement. Mitral valve reconstruction has become the standard treatment for *mitral regurgitation* (MR), replacing *MV replacement* (MVR) because of its superiority in-terms of operative mortality, late survival, freedom from thromboembolic accidents, endocarditis, recurrent MR and re-operation. MVr replacing MVR as the preferred choice of surgery for MVD has been a gradual process that began from 1985. Published data have demonstrated that MVr is feasible in 95% of patients with *degenerative MR* (dMR), in about 75% of patients with *ischemic MR* (iMR) and in 70% of *rheumatic MR* (rMR) cases [16]. However, reports from the United States and the Euro Heart Survey show that only 44.3% and 46.5% respectively of patients who require MV surgery get a MV reconstruction [25]. Even MV repair has been proven in several studies to be superior to MV replacement, it is difficult for some surgeons to shift from placement to repair simply because they are more familiar with replacement.

The superiority of MVr over MVR is associated with the preservation of the valve structures in the reconstructive process (which are normally excised in replacement procedures). DeBouche and associates in their long-term follow-up of patients after MVr plus annuloplasty using a Carpentier-Edwards ring or glutaraldehyde-treated bovine pericardium, reported a 15-year 76% and 93% freedom from redo surgery in rMR and dMR respectively [16]. These results were corroborated by Duran, Galloway and others in separate studies. In a study on extremely complex dMVD, Gillinov et al. reported survival as more dependent on comorbidities than on the type of MV surgery [20]. This is disputable because if the MVD is extremely complex, the valve most probably will be irreparable making MVR the obvious choice. Moreover, the effect of comorbidities on survival is dependent on the kind of organs involved and the level of severity.

In the Mayo Clinic long-term results of MVr for either anterior or posterior leaflet (AL or PL) pathologies that included *coronary artery disease* (CAD) patients, valve reconstruction was found to be superior to its replacement though the rate of reoperation was the same [35]. So, even in concomitant cardiac diseases, MVr supersedes MVR. When the same authors compared AL repair to PL, they recorded a higher reoperation rate for AL demonstrating the complexity of AL lesions. In an update of the study, the post-MVr life expectancy was similar among both the elderly and young patients [17]. Therefore, the decision to perform MVr for MVD should be based on the valve morphology and not the patient's age.

DiBardino et al. reported that at some point, long survivors of repair of rMVD will require a redo surgery and that MVr in *functional MR* (fMR) is less effective [14]. On the contrary, about a decade earlier, Carpentier performed a series of isolated repairs of rMVD reporting a 55%±25% 20-year freedom from re-operation [8]. His report of a 48% 20-year survival of MVr in dMVD [49] was corroborated by DiBardino et al. in study of MVr with concomitant cardiac surgeries. Their in hospital and long-term mortality of valve reconstruction were as low as 2.3% and 7.8% respectively. Nonetheless there are still skepticisms concerning the very-long durability of MVr.

When it comes to reconstruction of MV due to *infective endocarditis* (ieMVD), the foremost step is extensive excision of the infected valve tissue. Repair is considered only after complete debridement of the diseased portions of the valve (Fig. 1). If after infected tissue resection, the valve is deemed not salvageable, MVR with mechanic prosthesis is used for younger patients with a native-valve IE, MVR with bioprosthesis is considered for patients older than 60 years with either prosthetic or native valve endocarditis and also for younger patients with prosthetic endocarditis [36]. Very often, *autologous pericardium* (Ape) is used as a patch to treat leaflet perforations and defects after tissue debridement or abscess excision. Dreyfus et co. reported positive results in the use of Ape in repair of ieMVD [18].

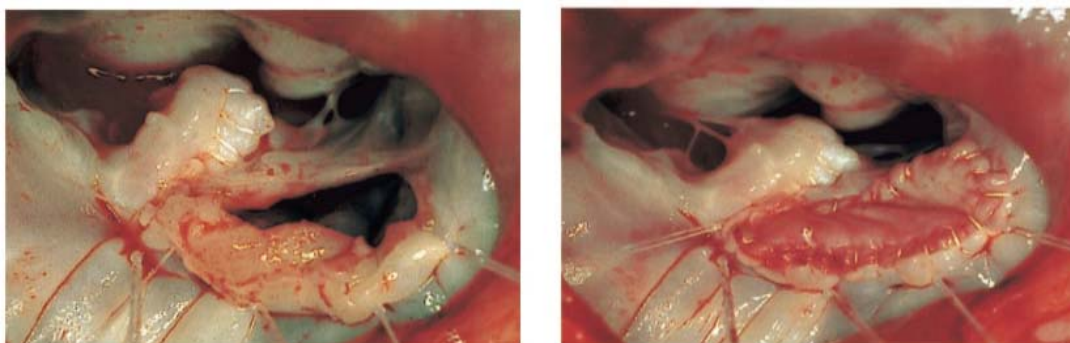


Fig. 1 Severe bacterial endocarditis of posterior leaflet. Completion of aggressive broad excision of infected tissue leaving a big gap in remaining tissue preventing. Valvuloplasty with pericardial patch as substitute for posterior leaflet. Reproduced from Ng et al.

Need for ring implantation. Reinforcement of the *mitral annulus* (MA) with a ring is an integral part of all MVr procedures. Annuloplasty rings/bands remodel and stabilize the MA to ensure repair durability. Ring/band implantation prevents progression of MV area enlargement whilst transforming the anatomical bicuspid valve in to a functional monocuspid valve [13]. An analysis from the Brigham and Women's Hospital concluded that without ring implantation, the 5-year freedom from post-repair progression of *myxomatous MVD* (mMVD) is only $67\pm 12\%$ [11]. It has been shown in animal models that without ring support in edge-to-edge repair, the systolic stress on the MA and leaflets can be overwhelming, leading to procedure-related failures [37]. Cohan and associates also reported a high risk of recurrent MR in repair of mMVD without annular reinforcement [38].

According to Carpentier, an annuloplasty ring is needed:

- (I) to restore the size and shape of the native annulus;
- (II) to prevent further annular dilatation; and
- (III) to provide functional annular support.

Therefore, he designed the annuloplasty ring to remodel the annulus into its systolic shape because the MV experiences the greatest stress during systole [6]. Early generations of prosthetic rings and bands improved leaflet coaptation at the expense of normal leaflet dynamics. As Carpentier famously stated, "*One may define the aim of valve reconstruction as restoring normal valve function rather than normal valve anatomy*" [42], restoring native annular dynamics has not always been the focus of valve reconstruction. David et al. and DiBardino et al. in separate studies did not find any difference in reduction of the MV area between the rigid Carpentier ring and the flexible Duran ring [12]. However, they demonstrated that, the PL freezes after a *prosthetic mitral annuloplasty* (PrMA) and valve closure was by the sole action of the AL. PrMA can reduce the mitral area by half. Bolling popularized the restrictive mitral annuloplasty technique to surgically undersize leaflets copatation for MR elimination [4].

Though different rings suit different of the MA, ring selection is still largely dependent on the operating surgeon's preference rather than evidence. Rigid, complete rings are designed to radically reshape a much-dilated annuli especially in LV dilatation. Flexible rings are design to preserve the changes in shape and form MV at each phase of the cardiac cycle. The physio-ring is designed to better match the annulus normal shape (Fig. 2). A ring that will suit all the forms of MVD is yet to be developed. However, these newer generations including the saddle-shape rings better reinforce the annulus and less hinder its dynamics.

Possible complications of PrMA include: pannus formation, fibrosis and calcification of the prosthetic ring[30]. Especially in *cardiomyopathic MR* (cmpMR), there are instances of recurrent MR despite ring implantation. This shows that prosthetic rings can be distorted over time[48], ring support does not completely fix the intertrigone distance in especially cmpMR and for effective leaflet coaptation and valve competence, the septo-lateral dimension must be reduced and fixed at a length[51]. It was for this reason that Edward Lifescences developed the GeoForm ring. MVr is also performed in paediatric cardiac surgery. Kalangos et al. in 2003 introduced a biodegradable annuloplasty ring that allows the native valve to grow whilst avoiding the use any foreign material on the annulus [27].

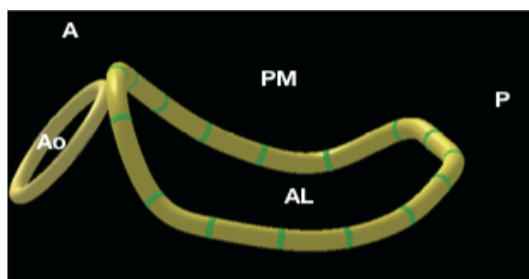


Fig. 2 3D of normal MV geometry with saddle-shaped annulus. AL, anterolateral; PM, posteromedial; A, anterior; P, posterior; Ao, aortic. annulus. Adapted from Wan S et. al.

Salati et co. introduced the use of pericardium for mitral annuloplasty [43]. They remodeled the posterior annulus with a pre-treated pericardial strip. Studies on the suitability of the pericardial tissue for annuloplasty have been contradicting. Whilst some studies reported Ape to be better than prosthetic rings in terms of preserving annular physiological dynamics, others reported the opposite. After associating *pericardial mitral annuloplasty* (PeMA) with repair failure and re-operation, Bevilacqua et co. compared posterior PeMA to posterior PrMA in dMVD patients with/without CAD and found out that PrMA was superior to PeMA in terms of 5-year freedom from re-operation and recurrent MR[1]. Likewise, Lorusso et co. reported that posterior PeMA was independently related to late repair failure when performed as an adjunct procedure to Alfieri's edge-to-edge MVr[29]. These two studies contradicted the report by Gillinov and co. that ring type (biological or prosthetic) had no effect on the longterm repair durability [21]. Unsuitability of Ape as an annuloplasty material has been associated with suture dehiscence of the ring or at the leaflet repair site [49].

As some studies report, PeMA enhances annular motion, ensures a more effective valve-orifice area in diastole during exercise and improves LV function [41]. PrMA on-the-other-hand transforms the MA from a saddle-shape to a planar configuration narrowing the intersection angle between the aortic and mitral-valvular planes [44]. This results in *systolic anterior motion* and *left ventricular outflow tract obstruction* (SAM and LVOTO). SAM with LVOTO reduces stroke volume leading to myocardial and systemic hypoperfusion, increased *left ventricular end diastolic volume* (LVEDV), LV hypertrophy and dilatation. This ends with *congestive heart failure* (CHF). In some cases, SAM is a temporary complication which resolves with volume loading or by the use of beta blockers [1]. Partial annular plication and the softness of the Ape have been cited as the reasons why PeMA maintains the physiological, non-planar configuration of the MA and enhances valvular-ventricular interaction [54].

Another advantage of Ape is its resistance to calcification. Studies on redo surgery due to procedural failure reported no signs of pericardial ring calcification or degeneration[54]. In large clinical series, pericardial tissue fixation with glutaraldehyde solution before usage in annuloplasty is reported to enhance its durability [54]. One can say that, Ape meets all the conventional criteria for an efficient and durable annuloplasty. A study that will firmly define the place of pericardial tissue in MVr is badly needed. Presently at our institution, 3rd Central Vishnevsky Military Hospital, we are performing a study to determine the suitability of Ape for mitral annuloplasty.

Techniques of mitral valve repair. The technique of MVr depends on the valve structure(s) involved in the pathologic process. Lesions of different valve structures present different challenges in repair. Some lesions are more difficult to repair than others making some reconstructive procedures superior to others in terms of durability etc. For example, as shown in several studies, PL repairs are usually easier and superior to AL repairs [7].

- The French Correction as introduced by Carpentier combines PL resection with sliding plasty to reconstruct an overgrown PL in *myxomatous mitral regurgitation* (mMR) to prevent SAM and LVOTO [26]. Normally, triangular resection is performed in limited AL or PL prolapse whilst quadrangular resection is performed for extensive PL prolapse. Risk of SAM is higher if the coaptation point is closer to the ventricular septum either because the residual PL is tall or the annuloplasty ring does not hold the enlarged leaflets properly [34].

- Alfieri *edge-to-edge* (EtE) technique transforms the single MV orifice into a *double orifice* (DO) mostly in AL lesions or bileaflet prolapse. Usually, after EtE, the annulus is reinforced with a ring to withstand the high systolic and diastolic pressures exerted on the DO valve. Without a ring implantation, the overall risk of recurrent MR is 11%, 23% in patients with annular calcification and 5% in those without calcification at just 3 years after EtE[2]. This technique violates one of the fundamental principles of MV repair- preserving leaflet mobility and at times is complicated by MV stenosis or leaflet fibrosis [37].

- Chordal shortening is performed to reduce the length of elongated chordae tendinae in degenerative or congenital MVD. Gillinov et co. reported a 10-year 89% success rate of chordal shortening[20]. In a study by DiBardino et al. 11% of the participants had a 3+/4+ recurrent MR within 1 year of chordal shortening[5]. Up-to-

date, there is still much skepticism about chordal shortening because of concerns of rupture at the site of insertion into the PM trench [47].

- *Chordal transposition/transfer* (Ct) and leaflet fixation on secondary chordae were introduced to treat AL prolapse due to chordal rupture. Most Ct procedures involve transfer of chords from tertiary or secondary positions to primary positions. Ct may also be a resection of PL chords and attaching them to prolapsing segments of the AL. Ct, though still performed in some centers has largely been replaced with synthetic chordal implantation. Duebener et al., in their studies on MVr reported that chordal replacement is safer than PL resection if leaflet prolapse is concomitant with MA calcification [28].

- *Mural annulus shortening suture* (MASS) technique is a modification of the Paneth-Burr annuloplasty [33]. One likely complication of MASS is the unintentional trauma of the *circumflex artery* (Cx) causing myocardial ischemia. Aybek and co. opined their support for MASS after recording an 83.2% 6-year freedom from nontrivial MR in their study [50].

- Commissurotomy is performed to free the valve leaflets from restricted movement in type IIIa MR as often seen in rMVd. Usually, it is performed in combination with another MVr procedure.

- Percutaneous techniques are revolutionizing how we treat MR. Percutaneous edge-to-edge plication with the Mitraclip was introduced for patients deemed too risky for open cardiac surgery. The NeoChord system percutaneously implants artificial chordae anchored to the apex via a small left thoracotomy on a beating heart. To treat iMR, Hvass et al. proposed bringing the two PM groups closer by tightening a Gore-Tex tube passed around their base [24]. Similar procedures that have been suggested are: intraventricular PM repositioning such as PM relocation, direct approximation of both PM, or approximation of PM tip to the MA [53]. It has also been suggested to treat cmpMR with the Acorn CorCap cardiac device. The *Carillon Mitral Contour System* (MCS) was developed for deployment in to the *coronary sinus* (CS) to push against the MV posterior leaflet in order to improve leaflets coaptation. Delivery of the MCS is not always possible because in some patients, the Cx and its branches lie between the MA and the CS making it vulnerable to compression. Also, in chronic iMR, the CS and PL are further apart due to structural remodeling limiting the possibility of a successful repair with the MCS [10].

- With technological advancement came techniques like magnetic annular narrowing, thermal annular shrinkage [31]. The Mitralign device is one of them. Ample Medical's PS3 system approaches the posterior annulus from the atrial septum and tethers a device from the P2 vicinity toward the atrial septum. Messa and co. researched the treatment of MR with cell transplantation [32]. In their investigation with sheep model, they showed that cell transfer in iMR promotes reverse remodeling and stabilizes the infarcted ventricle. This to a particular extent reduced the severity of MR.

Though these newer techniques are less invasive as compared to open-surgery, none has been proven to be superior in terms of long-term durability. However, they might be superior in isolated cases or in special groups of patients. Most of these latest techniques have a long way to go for mass adoption.

Mitral annuloplasty with autologous pericardial ring. The rapid growth of the prosthetic-device market has dealt a great blow to any prospect of deep research and expansion of pericardial use in MV surgery. Available studies on Ape have been about its application in leaflet patching, posterior annuloplasty, reconstruction of LV wall aneurysms or for hemostasis in coronary artery anastomosis in aortic root replacement. Offering a reliable durability, the pericardial tissue is also used as a straddling endoventricular pericardial patch to avoid LV rupture after en bloc decalcification [15].

When MR is as a result of extensive leaflet damage, the reconstructive technique depends on the amount of unaffected leaflet tissue left after debridement [15]. Pericardial tissue is used to patch and extend remnants of leaflets after excision. Ng et al. pointed out that in MVr Ape when treated with *glutaraldehyde* (GTH) is easy to handle and very pliable [9]. Some studies have advised against the use of fresh-untreated Ape because of the possibility of its progressive shrinkage, fibrosis, loss of pliability, early degeneration and the possibility of endocarditis [9]. Scrofani et al. in a study on MV remodeling after posterior annuloplasty with a pericardial band (band-PeMA) treated with GTH, reported that at re-operation, each pericardial band was completely endothelialized and was indistinguishable from the atrial endocardium [23]. According to some reports, PeMA has excellent long-term results in terms of prevention of recurrent MR [46]. Except in the case of fMR (due to annular dilatation), annuloplasty is usually performed concomitantly with a major MVr procedure.

In our study, we perform annuloplasty with a *pericardial ring* (ring-PeMA) either as a major procedure in isolated MA dilatation or as adjunct to a major MVr procedure in organic MVI. It is our opinion that irrespective of leaflet involvement and MVr type, ring-PeMA rather than band-PeMA will provide more stability and durability (Fig. 3). Each mattress suture on the annulus plicates and reduces its circumference by a fraction of a centimeter. Sewing 12 or more mattress sutures over the entire annulus, implantation of the pericardial and adjusting the ring size to achieve tangible leaflet coaptation should be adequate to restore the function of the MV. Based on our midterm results, PeMA can be considered superior to PrMA in-terms of preservation of annulus dynamics, cost of treatment, risks of infection and complications such as haemolytic anaemia. Each of the 75 patients in our research had a preoperative *transthoracic echocardiography* (TTE) and *transesophageal echocardiography* (TEE), intraoperative TEE, postoperative TTE at 10 days, 6, 12, 24 and 36 months. Participants or their cardiologists

ogists mailed answered ques tionnaires on QoL to us. We compare the outcome of our PeMA to that of PrMA of other studies. At the moment our mean follow-up time is 18 ± 6 month and freedom from reapportion at this stage is 100%. During routine checkups, all patients reported an improvement in QoL, the control TTE data also showed reduction in MR, left atrial diameter, pulmonary artery systolic pressure and improvement of LV function. We plan to publish the complete outcome in the summer of 2020.

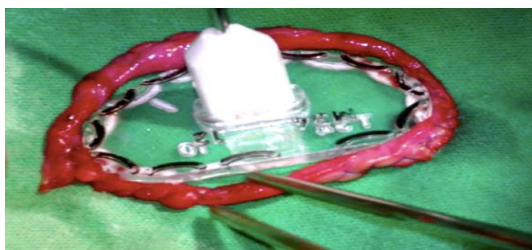

Fig. 3 Annuloplasty ring sewn from the autologous pericardium. Using a sizer to correctly determine the circumference of the needed ring. Attachment of the Ape ring to the mitral annulus

Pericardial tissue fixation. There are different proposals on how the pericardial tissue should be treated before use in MV surgery. Pericardial resistance to calcification has been shown to be dependent on the method of fixation. GTH has been associated with devitalization of the intrinsic connective tissue cells of bioprostheses causing the breakdown of transmembrane calcium regulation therefore contributing to cell-associated calcific deposits [45]. In the 1990s, Chauvaud and co. reported successful MVr with Ape after its 15-minute treatment with GTH [55]. However, Walter and al. in a study on the use of untreated Ape in MV annuloplasty in children advised against treating the pericardial tissue with GTH in order to preserve its flexibility. They described an untreated Ape as a source of soft reinforcement that conforms to the natural tridimensional geometry of the MA, and maintains the normal physiologic movement of the MA whilst offering long-term durability [3]. The same authors cited the absence of thrombogenicity and calcification at reoperation as evidence of the safety and durability of the untreated pericardial tissue. Reports that GTH causes calcification of biological tissues were contradicted in a study that demonstrated a 19-year freedom from calcification of a GTH-treated patch[56]. By judgment, GTH to some extent ensures bio-tissue durability and protects it against degeneration whilst precipitating the calcification.

Xenopericardium is also a source of material for annuloplasty after MVr. This is however not a common practice in cardiac surgery because of the risks of antigenicity or transmission of infectious diseases such as HIV AIDS. In redo surgery when the remnant of Ape is not suitable or adequate for usage, a preserved xenopericardium or even heteropericardium can be used. In pediatric MVr, posterior PeMA with an untreated Ape stabilizes the MA allowing it to remodel according to age. PeMA in pediatric patients allows growth of the MV complex over time and ensures the free movement of the MA [39].

It is the duty of health-providers to reduce the cost of healthcare by providing the most cost-effective treatments possible. Not so much is known about the cost-effectiveness of the various surgical MVr techniques. Data from studies on the cost of treatment of MR are usually related to shorter hospital stays, more affordable devices, etc. There is lack of information on the short-, mid-, or long-term costs relative to the clinical outcomes of different treatment methods. Beresniak et co. in a 10-year model stimulation study reported a lower medical cost for MVr than biologic and mechanical MVR (€31,414 versus €35,501 and €38,499, respectively) [1]. The lower cost of MVr can be associated with avoidance of device implantation, anticoagulation therapy and management of prosthesis-related complications such thromboembolism, recurrent MR, etc. Comparing PeMA and PrMA cost-wisely will undoubtedly provide similar results because an Ape is totally free-of-charge whereas the use of a prosthetic ring or band incurs some cost. If a repair technique is long-lasting, the risks of redo surgery are low making the method cost-effective. The idea that PeMA minimally affects the MV dynamics, improves LV function and promotes reverse remodeling makes it a better option in terms of durability and hence, more cost-effective. Around the world, most cardiac centers are stated-owned or state-sponsored because of the high-cost of cardiac surgeries. Yearly, more than 300,000 people worldwide, 44,000 in the United States alone, undergo open-heart surgery due to MVD. A repair plus annuloplasty technique that will match or be superior to MVR will have a great economic impact and enable many centers to expand their services to include more needy people.

Causes of repair failure. Risk factors of MVr failure include: advanced myxomatous changes of valve leaflets, chordal shortening procedures, failure to perform an annuloplasty, residual MR at repair completion, NYHA functional class III or IV and concomitant cardiac procedures. In 1997, Gillinov and co. in a study of MVr failure classified the causes of repair failure as either Procedure-related or Valve-related [22].

According to this study, procedure-related failure may be due to rupture of a shortened chord at the site of insertion into the papillary muscle, suture dehiscence of annuloplasty ring or leaflet repair site or incomplete initial repair. On-the-other-hand, valve-related failure is associated with progression of native valve disease (rupture, elongation of untreated chords), endocarditis or postoperative leaflet retraction. At redo surgeries, they reported that among MVr of dMVD patients, 70% of repair failures were procedure-related and in MVr of rMVD patients, 87% of repair failures were valve-related. Therefore, procedure-related failure is predominant in repair of dMVD whilst valve-related failure is more common in repair of rMVD. They also reported the interval between initial repair and redo surgery to be shorter in dMVD than in rMVD.

Conclusion. Surgery for mitral regurgitation (MR) has evolved since its inception six decades ago. The surgical techniques have gone from valve repair to valve replacement, back to valve repair and now shifting towards percutaneous/transcatheter procedures. The need for the best treatment in terms of durability, accessibility, cost-effectiveness has led to this evolution. Valve repair plus annuloplasty with a pericardial is a promising technique that will yield wonderful results if duly researched. Nonetheless, we are still far away from the PERFECT treatment that every cardiac-surgeon will agree to. This emphasizes the importance of continuous improvement on existing methods and innovation of more techniques.

Literature

1. Ariel B., Brigitte S., Paul A., Philippe M., Jean-Noel F. Cost-effectiveness of mitral valve repair versus replacement by biologic or mechanical prosthesis // *Ann Thorac Surg* 2013. №95. P. 98–104.
2. Bhudia S.K., McCarthy P.M., Smedira N.G., Lam B.K., Rajeswaran J., Blackstone E.H. Edge-to-edge (Alfieri) mitral repair: results in diverse clinical settings // *Ann Thorac Surg*. 2004. №77. P. 1598–1606.
3. Block P.C. Percutaneous transcatheter repair for mitral regurgitation // *J Interv Cardiol*. 2006. №19. P. 547–551.
4. Bolling S.F., Pagani F.D., Deeb G.M., Bach D.S. Intermediate-term outcome of mitral reconstruction in cardiomyopathy // *J Thorac Cardiovasc Surg*. 1998. №115. P. 381–386.
5. Brinster D.R., Unic D., D'Ambra M.N. Midterm results of the edge-to-edge technique for complex mitral valve repair // *Ann Thorac Surg*. 2006. №81. P. 1612–1617.
6. Carpentier A.F., Lessana A., Relland J.Y. The "physioring": an advanced concept in mitral valve annuloplasty // *Ann Thorac Surg* 1995. №60. P. 1177–1185.
7. Castro L.J., Moon M.R., Rayhill S.C. Annuloplasty with flexible or rigid ring does not alter left ventricular systolic performance, energetics or ventricular-arterial coupling in conscious, closed-chested dogs // *J Thorac Cardiovasc Surg*. 1993. №105. P. 643–659.
8. Chauvaud S., Fuzellier J.F., Berrebi A. Long term (29 years) results of reconstructive surgery in rheumatic mitral valve insufficiency // *Circulation*. 2001. №104. P. 2-5.
9. Choi-Keung N., Joachim N., Christian P., Otmar P., Johannes A., Herbert F., Peter H. Valvuloplasty with glutaraldehyde-treated autologous pericardium in patients with complex mitral valve pathology // *Ann Thorac Surg* 2001. №71. P. 78–85.
10. Choure A.J., Garcia M.J., Hesse B., Sevensma M., Maly G., Greenberg N.L., Borzi L., Ellis S., Tuzcu E.M., Kapadia S.R. In vivo analysis of the anatomical relationship of coronary sinus to mitral annulus and left circumflex coronary artery using cardiac multidetector computed tomography: implications for percutaneous coronary sinus mitral annuloplasty // *J Am Coll Cardiol*. 2006. №48. P. 1938–1945.
11. Cohn L.H., Couper G.S., Aranki S.F., Rizzo R.J., Kinchla N.M., Collins J.J.Jr. Long-term results of mitral valve reconstruction for regurgitation of the myxomatous mitral valve // *J Thorac Cardiovasc Surg* 1994. №107. P. 143–151.
12. Cohn L.H., DiSesa V.J., Couper G.S. Mitral valve repair for myxomatous degeneration and prolapse of the mitral valve. // *J Thorac Cardiovasc Surg*. 1989. №98. P.987–993.
13. David T.E., Armstrong S., Sun Z., Daniel L. Late results of mitral valve repair for mitral regurgitation due to degenerative disease // *Ann Thorac Surg* 1993. №56. P. 7–14.
14. David T., Burns R., Bacchus C. Mitral regurgitation with and without preservation of chordae tendinae // *J Thorac Cardiovasc Surg*. 1984. №88. P. 718–725.
15. David T.E., Feindel C.M., Armstrong S., Sun Z. Reconstruction of the mitral anulus. A ten-year experience // *J Thorac Cardiovasc Surg* 1995. №110. P. 1323–1332.
16. Deloche A., Jebara V.A., Relland J.Y., Chauvaud S., Fabiani J.N., Perier P. Valve repair with Carpentier techniques: the second decade // *J Thorac Cardiovasc Surg* 1990. №99. P. 990–1002.
17. Detaint D., Sundt T.M., Nkomo V.T. Surgical correction of mitral regurgitation in the elderly: outcomes and recent improvements // *Circulation*. 2006. №114(4). P. 265–272.
18. Dreyfus G., Serraf A., Jebara V.A. Valve repair in acute endocarditis // *Ann Thorac Surg* 1990. №49. P. 706–711.

19. Gillinov A.M., Blackstone E.H., Alaulaqi A.. Outcomes after repair of the anterior mitral leaflet for degenerative disease // *Ann Thorac Surg*. 2008. №86. P. 708–717.
20. Gillinov A.M., Blackstone E.H., Nowicki E.R. Valve repair versus valve replacement for degenerative mitral valve disease // *J Thorac Cardiovasc Surg* 2008. №135. P. 885–893.
21. Gillinov A.M., Cosgrove D.M., Lytle B.W., Taylor P.C., Stewart R.W., McCarthy P.M. Reoperation for failure of mitral valve repair // *J Thorac Cardiovasc Surg*. 1997. №113. P. 467–475.
22. Gillinov A.M., Cosgrove D.M., Blackstone E.H., Diaz R., Arnold J.H., Lytle B.W., Smedira N.G., Sabik J.F., McCarthy P.M., Loop F.D. Durability of mitral valve repair for degenerative disease // *J Thorac Cardiovasc Surg*. 1998. №116. P.734–743.
23. Gogbashian A., Sepic J., Soltesz E.G., Nascimben L., Cohn L.H. Operative and long term survival of elderly is significantly improved by mitral valve repair // *Am Heart J*. 2006. №151. P. 1325–1333.
24. Hvass U., Tapia M., Baron F.. Papillary muscle sling: a new functional approach to mitral repair in patients with ischemic left ventricular dysfunction and functional mitral regurgitation // *Ann Thorac Surg*. 2003. №75. P. 809–811.
25. Iung B., Baron G., Butchart E.G., Delahaye F., Gohlke-Barwolf C., Levang O.W., Tornos P., Vanovershelde J.L., Vermeer F., Boersma E., Ravaud P., Vahanian A. A prospective survey of patients with valvular heart disease in Europe: the Euro Heart Survey on Valvular Heart Disease // *Eur Heart J*. 2003. №24. P. 1231–1243.
26. Jebara V.A., Mihaileanu S., Acar C., Brizard C., Grare P., Latremouille C., Chauvaud S., Fabiani J.N., Deloche A., Carpentier A. Left ventricular outflow tract obstruction after mitral valve repair: results of the sliding leaflet technique // *Circulation*. 1993. №88. P. 30–34.
27. Kalangos A., Christenson J.T., Beghetti M. Mitral valve repair for rheumatic valve disease in children: midterm results and impact of the use of a biodegradable mitral ring // *Ann Thorac Surg* 2008. №86. P. 161–168.
28. Lennart F.D., Olaf W., Niko N., Thomas G., Roland F., Hans-Joachim S. Mitral-valve repair without annuloplasty rings: results after repair of anterior versus posterior defects using polytetrafluoroethylene sutures for chordal replacement // *European Journal of Cardio-thoracic Surgery*. 2000. №17. P. 206–212.
29. Lorusso R., Borghetti V., Totaro P., Parrinello G., Coletti G., Minzioni G. The double-orifice technique for mitral valve reconstruction: predictors of postoperative outcome. // *Eur J Cardiothorac Surg*. 2001. №20. P. 583–589.
30. Luk A., Jegatheeswaran A., David T.E. Redo mitral valve surgery: morphological features. // *Cardiovasc Pathol*. 2008. №17. P. 309–317.
31. Mack M.J. Coronary sinus in the management of functional mitral regurgitation: the mother lode or fool's gold? // *Circulation*. 2006. №114. P. 363–364.
32. Messas E., Bel A., Morichetti M.C., Carrion C., Handschumacher M.D., Peyrard S., Vilquin J.T., Desnos M., Bruneval P., Carpentier A., Menasche P., Levine R.A., Hagege A.A. Autologous myoblast transplantation for chronic ischemic mitral regurgitation // *J Am Coll Cardiol*. 2006. №47. P. 2086–2093.
33. Michael N., Thomas S., Akihiro I., Markus P., Maren S., Christian B. Elevated mitral valve pressure gradient after mitralclip implantation deteriorates long-term outcome in patients with severe mitral regurgitation and severe heart failure // *J Am Coll Cardiol Interv*. 2017. №10. P. 931–939.
34. Mihaileanu S., Marino J.P., Chauvaud S., Perier P., Forman J., Vissoat J., Julien J., Dreyfus G., Abastado P., Carpentier A. Left ventricular outflow obstruction after mitral valve repair (Carpentier's technique): proposed mechanisms of disease // *Circulation*. 1988. №78. P. 78–84.
35. Mohty D., Orszulak T.A., Schaff H.V. Very long-term survival and durability of mitral valve repair for mitral valve prolapse // *Circulation*. 2001. №104. P. 1–7.
36. Moon M.R., Miller D.C., Moore K.A. Treatment of endocarditis with valve replacement: the question of tissue versus mechanical prosthesis // *Ann Thorac Surg*. 2001. №71. P. 1164–1171.
37. Nielsen S.L., Timek T.A., Lai D.T. Edge-to-edge mitral repair: tension on the approximating suture and leaflet deformation during acute ischemic mitral regurgitation in the ovine heart // *Circulation*. 2001. №104. P. 29–35.
38. Paul W.M. Fedak, Patrick M. McCarthy, Robert O. Bonow. Evolving concepts and technologies in mitral valve repair // *Circulation*. 2008. №117. P. 963–974. DOI: 10.1161/CIRCULATION.AHA.107.702035.
39. Perier P., Stumpf J., Götz C., Lakew F., Schneider A., Clausnizer B. Valve repair for mitral regurgitation caused by isolated prolapse of the posterior leaflet // *Ann Thorac Surg*. 1997. №64. P. 445–450.
40. Rappaport E. Natural history of aortic and mitral valve disease // *Am J Cardiol*. 1975. №35. P. 221–227.
41. Rassi Jr. A., Crawford M.H., Richards K.L., Miller J.F. Differing mechanisms of exercise flow augmentation at the mitral and aortic valves // *Circulation*. 1988. №77. P. 543–551.
42. Ryomoto M., Mitsuno M., Yamamura M. Is physiologic annular dynamics preserved after mitral valve repair with rigid or semirigid ring? // *Ann Thorac Surg*. 2014. №97. P. 492–497.

43. Salati M., Scorfani R., Santoli C. Posterior pericardial annuloplasty: a physiologic correction? // *Eur J Cardiothorac Surg.* 1991. №5. P. 226–229.
44. Schiavone W.A., Cosgrove D.M., Lever H.M., Stewart W.J., Salcedo E.E. Long-term follow-up of patients with left ventricular out low tract obstruction after Carpentier ring mitral annuloplasty // *Circulation.* 1988. №78. P. 60–65.
45. Schoen F.J., Tsao J.W., Levy R.J. Calcification of bovine pericardium used in cardiac valve bioprostheses: implications for the mechanism of bioprosthetic tissue mineralization // *Am J Pathol.* 1986. №123. P. 134–145.
46. Scrofani R., Moriggia S., Salati M., Fundaro P., Danna P., Santoli C. Mitral valve remodelling: long-term results with posterior pericardial annuloplasty // *Ann Thorac Surg.* 1996. №61. P. 895–899.
47. Smedira N.G., Selman R., Cosgrove D.M., McCarthy P.M., Lytle B.W., Taylor P.C. Repair of anterior leaflet prolapse: chordal transfer is superior to chordal shortening // *J Thorac Cardiovasc Surg.* 1996. №112. P. 287–292.
48. Spoor M.T., Geltz A., Bolling S.F. Flexible versus nonflexible mitral valve rings for congestive heart failure: differential durability of repair // *Circulation.* 2006. №114. P.67–71.
49. Stefano B., Alfredo G.C., Jacopo G., Umberto P., Massimiliano M., Sacha M., Enkel K., Mattia G. Mitral valve repair for degenerative disease: is pericardial posterior annuloplasty a durable option? // *European Journal of Cardio-thoracic Surgery.* 2003. №23. P. 552–559.
50. Tayfun A., Petar R., Aleksandra M., Andreas S., Selami D., Ulf Abdel-Rahman., Anton M. Seven years' experience with suture annuloplasty for mitral valve repair // *J Thorac Cardiovasc Surg.* 2006. №131. P. 99–106. DOI:10.1016/j.jtcvs.2005.07.060.
51. Tibayan F.A., Rodriguez F., Langer F., Zasio M.K., Bailey L., Liang D., Daughters G.T., Ingels N.B.Jr, Miller D.C. Does septal-lateral annular cinching work for chronic ischemic mitral regurgitation? // *J Thorac Cardiovasc Surg.* 2004. №127. P. 654–663.
52. Tribouilloy C., Enriquez-Sarano M., Schaff H. Impact of preoperative symptoms on survival after surgical correction of organic mitral regurgitation: rationale for optimizing surgical indications // *Circulation.* 1999. №99. P. 400–405.
53. Ueno T., Sakata R., Iguro Y. New surgical approach to reduce tethering in ischemic mitral regurgitation by relocation of separate heads of the posterior papillary muscle // *Ann Thorac Surg.* 2006. №81. P. 2324–2325.
54. Valentino B., Marco C., Carla S., Diego D., Pasquale T., Giuseppe C., Marco P., Roberto L. Biological versus prosthetic ring in mitral-valve repair: enhancement of mitral annulus dynamics and left-ventricular function with pericardial annuloplasty at long term // *European Journal of Cardio-thoracic Surgery* 2000. №17. P. 431–439.
55. Wan S., Lee A.P., Jin C.N., Wong R.H., Chan H.H., Ng C.S., Wan I.Y., Underwood M.J. The choice of mitral annuloplastic ring—beyond “surgeon’s preference” // *Ann Cardiothorac Surg.* 2015. №4(3). P. 261–265. DOI: 10.3978/j.issn.2225-319X.2015.01.05.
56. Yu S., Yukikatsu O., Michihiro N., Tadaaki K., Mitsuru Y., Takashi M., Naoto F., Yasunobu K. Late results of mitral valve repair with glutaraldehyde-treated autologous pericardium // *Ann Thorac Surg.* 2013. №95. P. 2000–2006.

References

1. Ariel B, Brigitte S, Paul A, Philippe M, Jean-Noel F. Cost-effectiveness of mitral valve repair versus replacement by biologic or mechanical prosthesis. *Ann Thorac Surg.* 2013;95:98-104.
2. Bhudia SK, McCarthy PM, Smedira NG, Lam BK, Rajeswaran J, Blackstone EH. Edge-to-edge (Alfieri) mitral repair: results in diverse clinical settings. *Ann Thorac Surg.* 2004;77:1598-606.
3. Block PC. Percutaneous transcatheter repair for mitral regurgitation. *J Interv Cardiol.* 2006;19:547-51.
4. Bolling SF, Pagani FD, Deeb GM, Bach DS. Intermediate-term outcome of mitral reconstruction in cardiomyopath. *J Thorac Cardiovasc Surg.* 1998;115:381-6.
5. Brinster DR, Unic D, D'Ambra MN. Midterm results of the edge-to-edge technique for complex mitral valve repair. *Ann Thorac Surg.* 2006;81:1612-7.
6. Carpentier AF, Lessana A, Relland JY. The "physioring": an advanced concept in mitral valve annuloplasty. *Ann Thorac Surg* 1995;60:1177-85.
7. Castro LJ, Moon MR, Rayhill SC. Annuloplasty with flexible or rigid ring does not alter left ventricular systolic performance, energetics or ventricular-arterial coupling in conscious, closed-chested dogs. *J Thorac Cardiovasc Surg.* 1993;105:643-59.
8. Chauvaud S, Fuzellier JF, Berrebi A. Long term (29 years) results of reconstructive surgery in rheumatic mitral valve insufficiency. *Circulation.* 2001;104:2-5.
9. Choi-Keung N, Joachim N, Christian P, Otmar P, Johannes A, Herbert F, Peter H. Valvuloplasty with glutaraldehyde-treated autologous pericardium in patients with complex mitral valve pathology. *Ann Thorac Surg* 2001;71:78-85.

10. Choure AJ, Garcia MJ, Hesse B, Sevensma M, Maly G, Greenberg NL, Borzi L, Ellis S, Tuzcu EM, Kapadia SR. In vivo analysis of the anatomical relationship of coronary sinus to mitral annulus and left circumflex coronary artery using cardiac multidetector computed tomography: implications for percutaneous coronary sinus mitral annuloplasty. *J Am Coll Cardiol.* 2006;48:1938-45.
11. Cohn LH, Couper GS, Aranki SF, Rizzo RJ, Kinchla NM, Collins JJr. Long-term results of mitral valve reconstruction for regurgitation of the myxomatous mitral valve. *J Thorac Cardiovasc Surg* 1994;107:143-51.
12. Cohn LH, DiSesa VJ, Couper GS. Mitral valve repair for myxomatous degeneration and prolapse of the mitral valve. *J Thorac Cardiovasc Surg.* 1989;98:987-93.
13. David TE, Armstrong S, Sun Z, Daniel L. Late results of mitral valve repair for mitral regurgitation due to degenerative disease. *Ann Thorac Surg* 1993;56:7-14.
14. David T, Burns R, Bacchus C. Mitral regurgitation with and without preservation of chordae tendinae. *J Thorac Cardiovasc Surg.* 1984;88:718-25.
15. David TE, Feindel CM, Armstrong S, Sun Z. Reconstruction of the mitral annulus. A ten-year experience. *J Thorac Cardiovasc Surg* 1995;110:1323-32.
16. Deloche A, Jebara VA, Relland JY, Chauvaud S, Fabiani JN, Perier P. Valve repair with Carpentier techniques: the second decade. *J Thorac Cardiovasc Surg* 1990;99:990-1002.
17. Detaint D, Sundt TM, Nkomo VT. Surgical correction of mitral regurgitation in the elderly: outcomes and recent improvements. *Circulation.* 2006;114(4):265-72.
18. Dreyfus G, Serraf A, Jebara VA. Valve repair in acute endocarditis. *Ann Thorac Surg* 1990;49:706-11.
19. Gillinov AM, Blackstone EH, Alaulaqi A. Outcomes after repair of the anterior mitral leaflet for degenerative disease. *Ann Thorac Surg.* 2008;86:708-17.
20. Gillinov AM, Blackstone EH, Nowicki ER. Valve repair versus valve replacement for degenerative mitral valve disease. *J Thorac Cardiovasc Surg* 2008;135:885-93.
21. Gillinov AM, Cosgrove DM, Lytle BW, Taylor PC, Stewart RW, McCarthy PM. Reoperation for failure of mitral valve repair. *J Thorac Cardiovasc Surg.* 1997;113:467-75.
22. Gillinov AM, Cosgrove DM, Blackstone EH, Diaz R, Arnold JH, Lytle BW, Smedira NG, Sabik JF, McCarthy PM, Loop FD. Durability of mitral valve repair for degenerative disease. *J Thorac Cardiovasc Surg.* 1998;116:734-43.
23. Gogbashian A, Sepic J, Soltesz EG, Nascimben L, Cohn LH. Operative and long term survival of elderly is significantly improved by mitral valve repair. *Am Heart J.* 2006;151:1325-33.
24. Hvass U, Tapia M, Baron F. Papillary muscle sling: a new functional approach to mitral repair in patients with ischemic left ventricular dysfunction and functional mitral regurgitation. *Ann Thorac Surg.* 2003;75:809-11.
25. Iung B, Baron G, Butchart EG, Delahaye F, Gohlke-Barwolf C, Levang OW, Tornos P, Vanoverschelde JL, Vermeer F, Boersma E, Ravaut P, Vahanian AA prospective survey of patients with valvular heart disease in Europe: the Euro Heart Survey on Valvular Heart Disease. *Eur Heart J.* 2003;24:1231-43.
26. Jebara VA, Mihaileanu S, Acar C, Brizard C, Grare P, Latremouille C, Chauvaud S, Fabiani JN, Deloche A, Carpentier A. Left ventricular outflow tract obstruction after mitral valve repair: results of the sliding leaflet technique. *Circulation.* 1993;88:30-4.
27. Kalangos A, Christenson JT, Beghetti M. Mitral valve repair for rheumatic valve disease in children: midterm results and impact of the use of a biodegradable mitral ring. *Ann Thorac Surg* 2008;86:161-8.
28. Lennart FD, Olaf W, Niko N, Thomas G, Roland F, Hans-Joachim S. Mitral-valve repair without annuloplasty rings: results after repair of anterior versus posterior defects using polytetrafluoroethylene sutures for chordal replacement. *European Journal of Cardio-thoracic Surgery.* 2000;17:206-12.
29. Lorusso R, Borghetti V, Totaro P, Parrinello G, Coletti G, Minzioni G. The double-orifice technique for mitral valve reconstruction: predictors of postoperative outcome. *Eur J Cardiothorac Surg.* 2001;20:583-9.
30. Luk A, Jegatheeswaran A, David TE. Redo mitral valve surgery: morphological features. *Cardiovasc Pathol.* 2008;17:309-17.
31. Mack MJ. Coronary sinus in the management of functional mitral regurgitation: the mother lode or fool's gold? *Circulation.* 2006;114:363-4.
32. Messas E, Bel A, Morichetti MC, Carrion C, Handschumacher MD, Peyrard S, Vilquin JT, Desnos M, Bruneval P, Carpentier A, Menasche P, Levine RA, Hagege AA. Autologous myoblast transplantation for chronic ischemic mitral regurgitation. *J Am Coll Cardiol.* 2006;47:2086-93.
33. Michael N, Thomas S, Akihiro I, Markus P, Maren S, Christian B. Elevated mitral valve pressure gradient after mitraclip implantation deteriorates long-term outcome in patients with severe mitral regurgitation and severe heart failure. *J Am Coll Cardiol Intv.* 2017;10:931-9.
34. Mihaileanu S, Marino JP, Chauvaud S, Perier P, Forman J, Vissoat J, Julien J, Dreyfus G, Abastado P, Carpentier A. Left ventricular outflow obstruction after mitral valve repair (Carpentier's technique): proposed mechanisms of disease. *Circulation.* 1988;78:78-84.
35. Mohty D, Orszulak TA, Schaff HV. Very long-term survival and durability of mitral valve repair for mitral valve prolapsed. *Circulation.* 2001;104:1-7.
36. Moon MR, Miller DC, Moore KA. Treatment of endocarditis with valve replacement: the question of tissue versus mechanical prosthesis. *Ann Thorac Surg.* 2001;71:1164-71.

37. Nielsen SL, Timek TA, Lai DT. Edge-to-edge mitral repair: tension on the approximating suture and leaflet deformation during acute ischemic mitral regurgitation in the ovine heart. *Circulation*. 2001;104:29-35.
38. Paul WM, Fedak, Patrick M, McCarthy, Robert O, Bonow. Evolving concepts and technologies in mitral valve repair. *Circulation*. 2008;117:963-74. DOI: 10.1161/CIRCULATION.AHA.107.702035.
39. Perier P, Stumpf J, Götz C, Lakew F, Schneider A, Clausnizer B. Valve repair for mitral regurgitation caused by isolated prolapse of the posterior leaflet. *Ann Thorac Surg*. 1997;64:445-50.
40. Rappaport E. Natural history of aortic and mitral valve disease. *Am J Cardiol*. 1975;35:221-7.
41. Rassi JrA, Crawford MH, Richards KL, Miller JF. Differing mechanisms of exercise flow augmentation at the mitral and aortic valves. *Circulation*. 1988;77:543-51.
42. Ryomoto M, Mitsuno M, Yamamura M. Is physiologic annular dynamics preserved after mitral valve repair with rigid or semirigid ring? *Ann Thorac Surg*. 2014;97:492-7.
43. Salati M, Scorfani R, Santoli C. Posterior pericardial annuloplasty: a physiologic correction? *Eur J Cardiothorac Surg*. 1991;5:226-9.
44. Schiavone WA, Cosgrove DM, Lever HM, Stewart WJ, Salcedo EE. Long-term follow-up of patients with left ventricular out low tract obstruction after Carpentier ring mitral annuloplasty. *Circulation*. 1988;78:60-5.
45. Schoen FJ, Tsao JW, Levy RJ. Calcification of bovine pericardium used in cardiac valve bioprostheses: implications for the mechanism of bioprosthetic tissue mineralization. *Am J Pathol*. 1986;123:134-45.
46. Scrofani R, Moriggia S, Salati M, Fundaro P, Danna P, Santoli C. Mitral valve remodelling: long-term results with posterior pericardial annuloplasty. *Ann Thorac Surg*. 1996;61:895-9.
47. Smedira NG, Selman R, Cosgrove DM, McCarthy PM, Lytle BW, Taylor PC. Repair of anterior leaflet prolapse: chordal transfer is superior to chordal shortening. *J Thorac Cardiovasc Surg*. 1996;112:287-92.
48. Spoor MT, Geltz A, Bolling SF. Flexible versus nonflexible mitral valve rings for congestive heart failure: differential durability of repair. *Circulation*. 2006;114:67-71.
49. Stefano B, Alfredo GC, Jacopo G, Umberto P, Massimiliano M, Sacha M, Enkel K, Mattia G. Mitral valve repair for degenerative disease: is pericardial posterior annuloplasty a durable option? *European Journal of Cardio-thoracic Surgery*. 2003;23:552-9.
50. Tayfun A, Petar R, Aleksandra M, Andreas S, Selami D, Ulf Abdel-Rahman., Anton M. Seven years' experience with suture annuloplasty for mitral valve repair. *J Thorac Cardiovasc Surg*. 2006;131:99-106. DOI:10.1016/j.jtcvs.2005.07.060.
51. Tibayan FA, Rodriguez F, Langer F, Zasio MK, Bailey L, Liang D, Daughters GT, Ingels NBJr, Miller D.C. Does septal-lateral annular cinching work for chronic ischemic mitral regurgitation? *J Thorac Cardiovasc Surg*. 2004;127:654-63.
52. Tribouilloy C, Enriquez-Sarano M, Schaff H. Impact of preoperative symptoms on survival after surgical correction of organic mitral regurgitation: rationale for optimizing surgical indications. *Circulation*. 1999;99:400-5.
53. Ueno T, Sakata R, Iguro Y. New surgical approach to reduce tethering in ischemic mitral regurgitation by relocation of separate heads of the posterior papillary muscle. *Ann Thorac Surg*. 2006;81:2324-5.
54. Valentino B, Marco C, Carla S, Diego D, Pasquale T, Giuseppe C, Marco P, Roberto L. Biological versus prosthetic ring in mitral-valve repair: enhancement of mitral annulus dynamics and left-ventricular function with pericardial annuloplasty at long term. *European Journal of Cardio-thoracic Surgery* 2000;17:431-9.
55. Wan S, Lee AP, Jin CN, Wong RH, Chan HH, Ng CS, Wan IY, Underwood MJ. The choice of mitral annuloplastic ring—beyond “surgeon’s preference”. *Ann Cardiothorac Surg*. 2015;4(3):261-5. DOI: 10.3978/j.issn.2225-319X.2015.01.05.
56. Yu S, Yukikatsu O, Michihiro N, Tadaaki K, Mitsuru Y, Takashi M, Naoto F, Yasunobu K. Late results of mitral valve repair with glutaraldehyde-treated autologous pericardium. *Ann Thorac Surg*. 2013;95:2000-6.

Библиографическая ссылка:

Ибн Сидики А., Лишук А.Н., Файбушевич А.Г., Иванов Д.В. Возможности кардиохирурга по замене митрального клапана // Вестник новых медицинских технологий. Электронное издание. 2019. №3. Публикация 1-10. URL: <http://www.medtsu.tula.ru/VNMT/Bulletin/E2019-3/1-10.pdf> (дата обращения: 13.06.2019). DOI: 10.24411/2075-4094-2019-16436. *

Bibliographic reference:

Ibn Sidiki A, Lishuk AN, Faibushevich AG, Ivanov DV. Vozmozhnosti kardiohirurga po zamene mitral'nogo klapana [A cardiac surgeon's perspective of mitral valve repair]. *Journal of New Medical Technologies, e-edition*. 2019 [cited 2019 June 13];1 [about 11 p.]. Russian. Available from: <http://www.medtsu.tula.ru/VNMT/Bulletin/E2019-3/1-10.pdf>. DOI: 10.24411/2075-4094-2019-16436.

* номера страниц смотреть после выхода полной версии журнала: URL: <http://medtsu.tula.ru/VNMT/Bulletin/E2019-3/e2019-3.pdf>